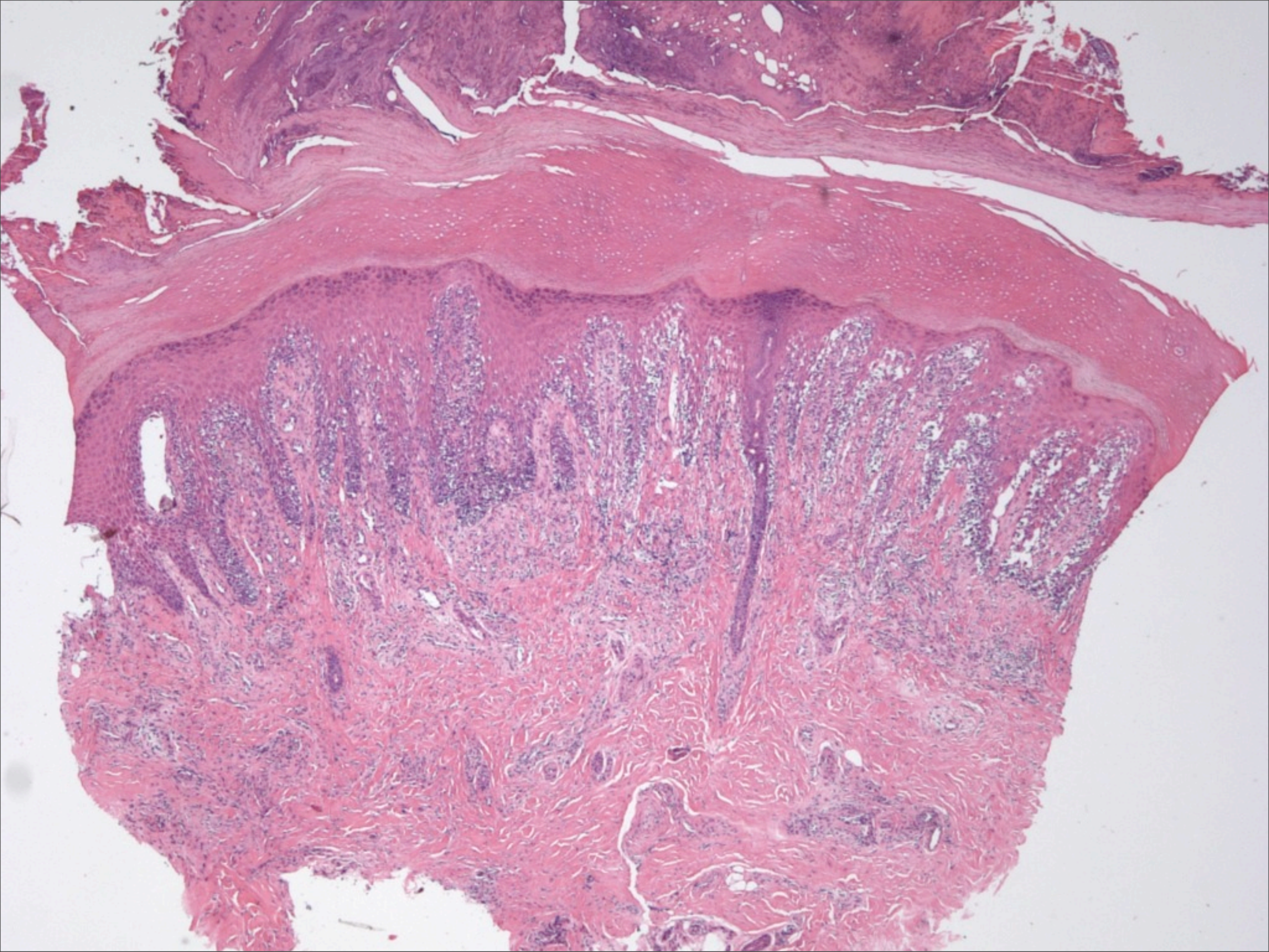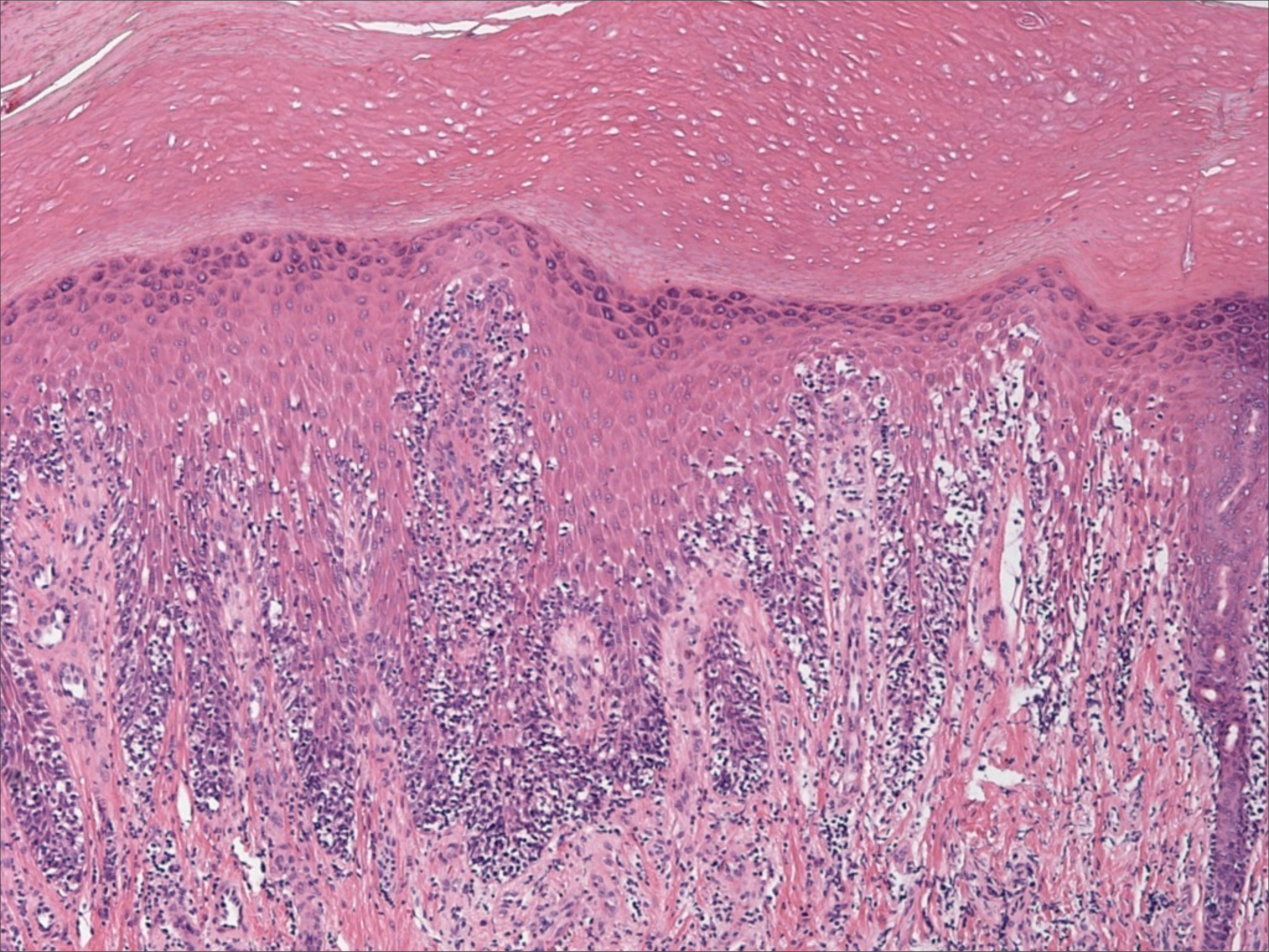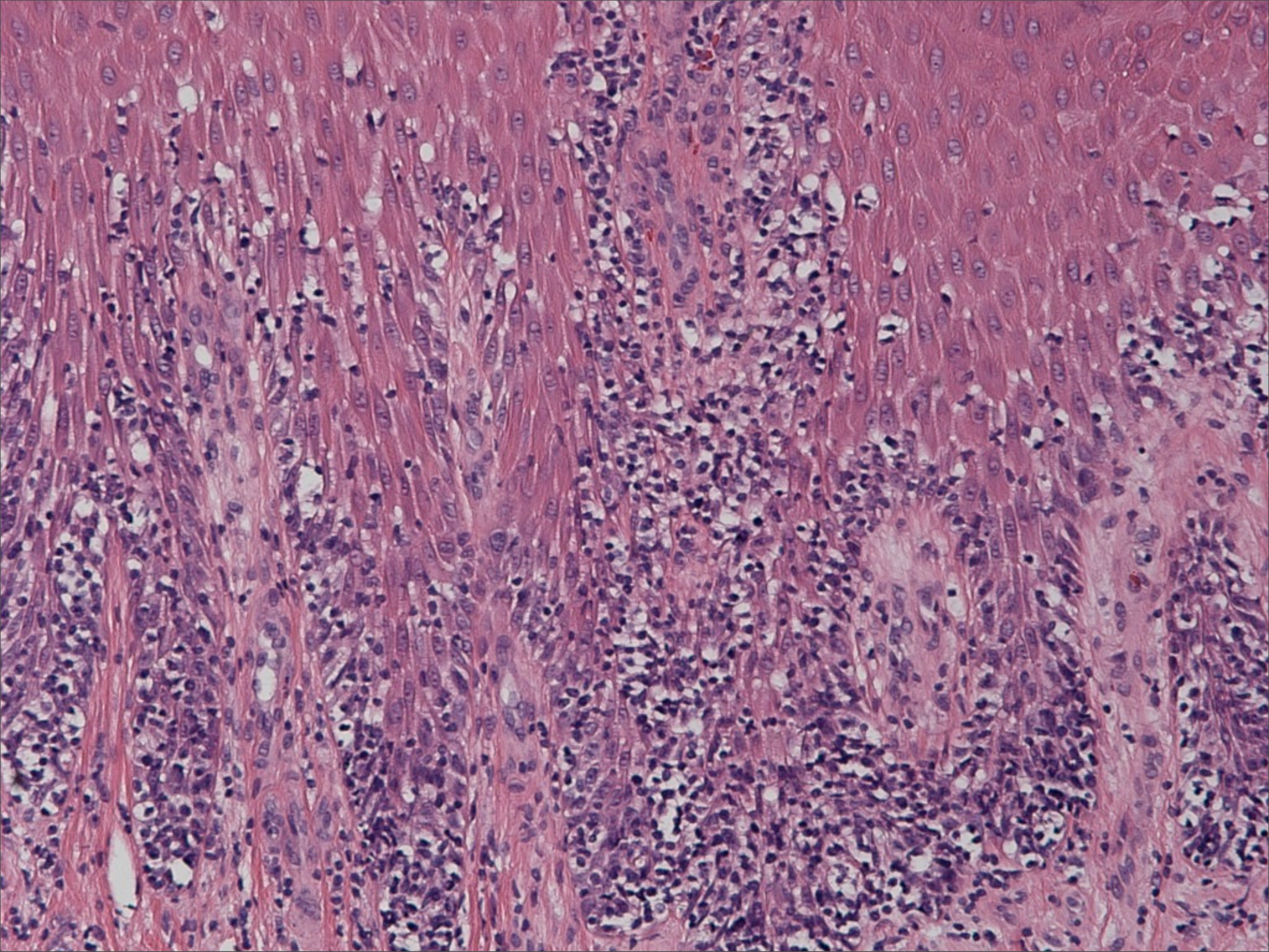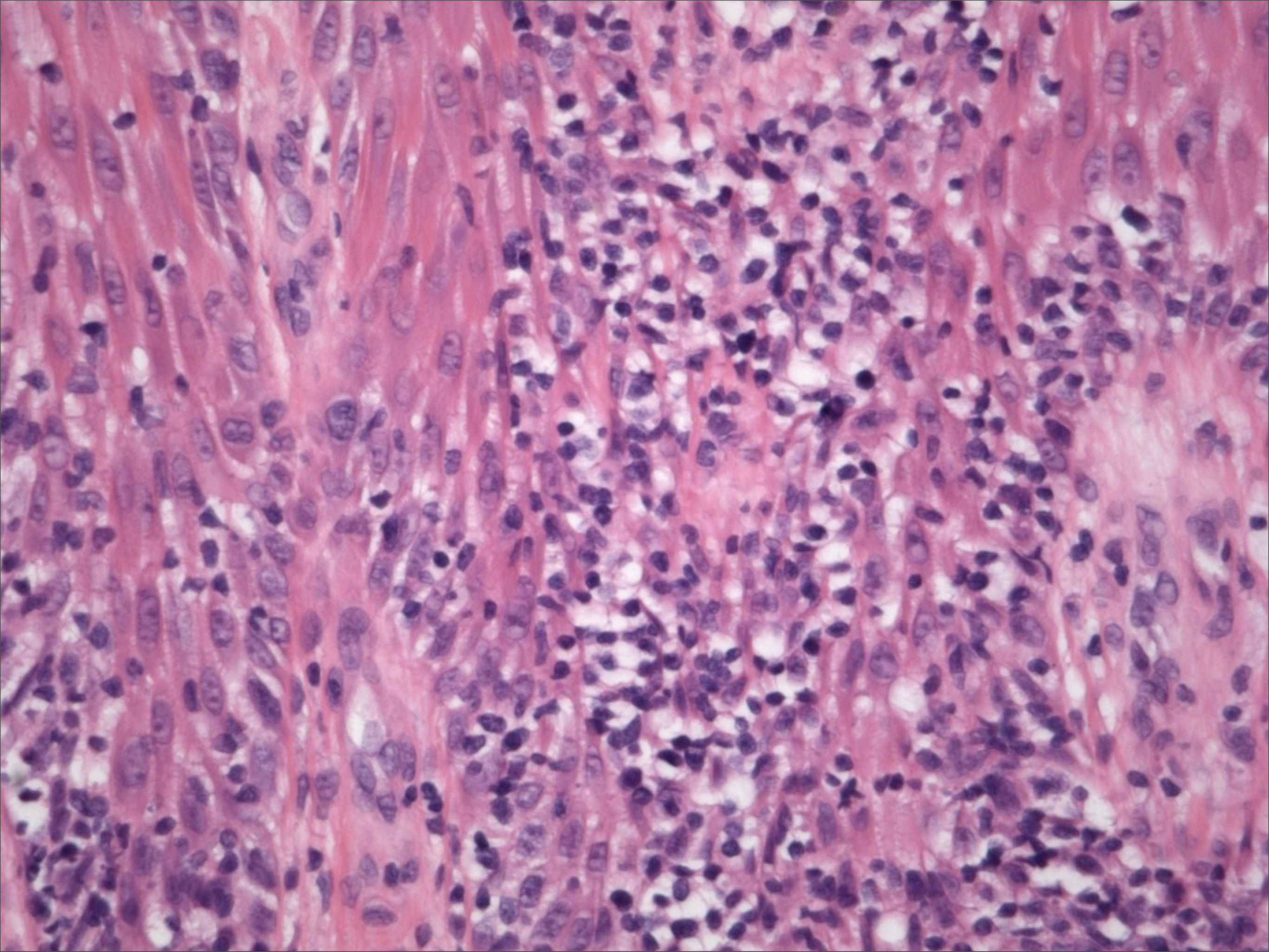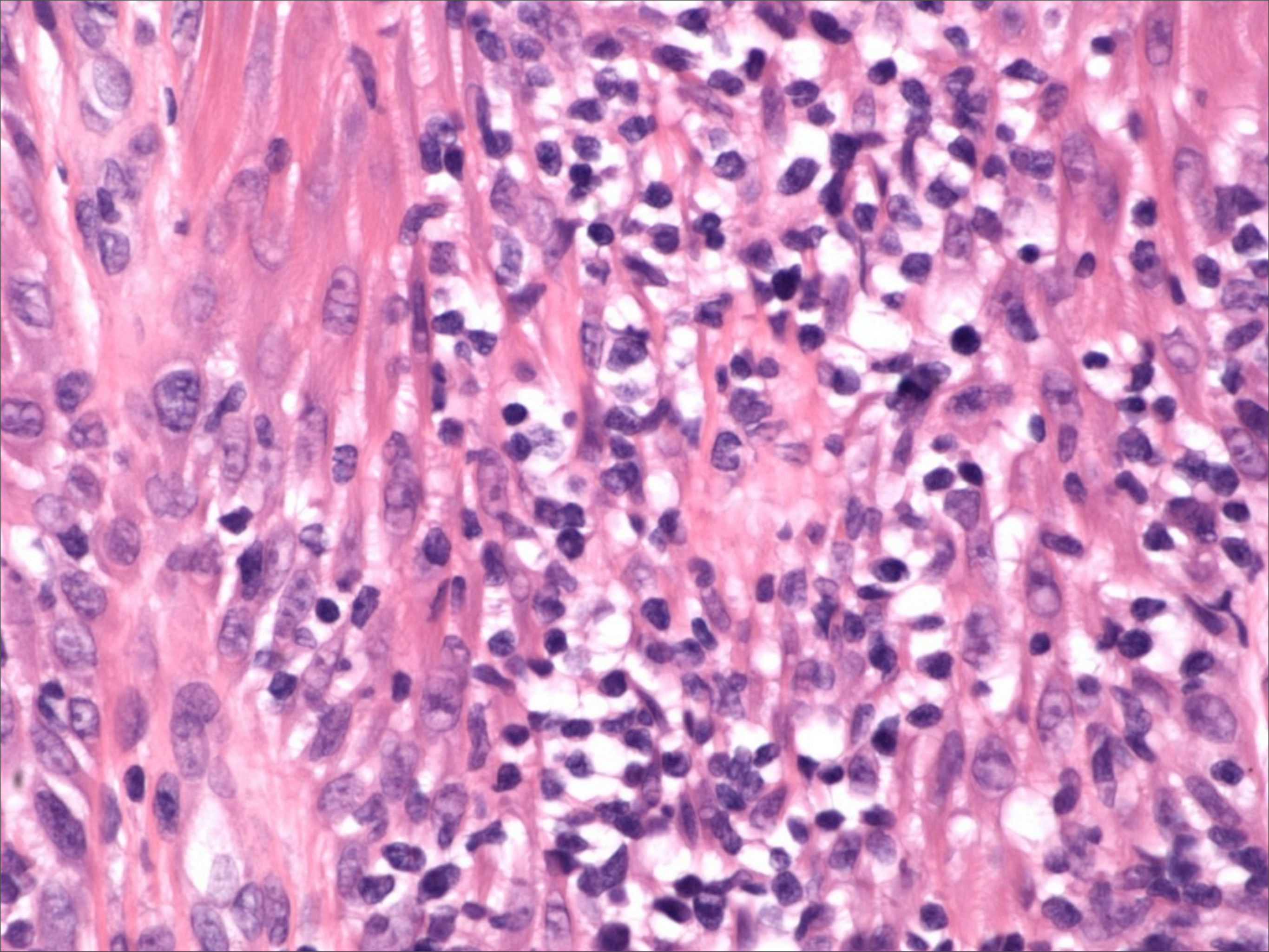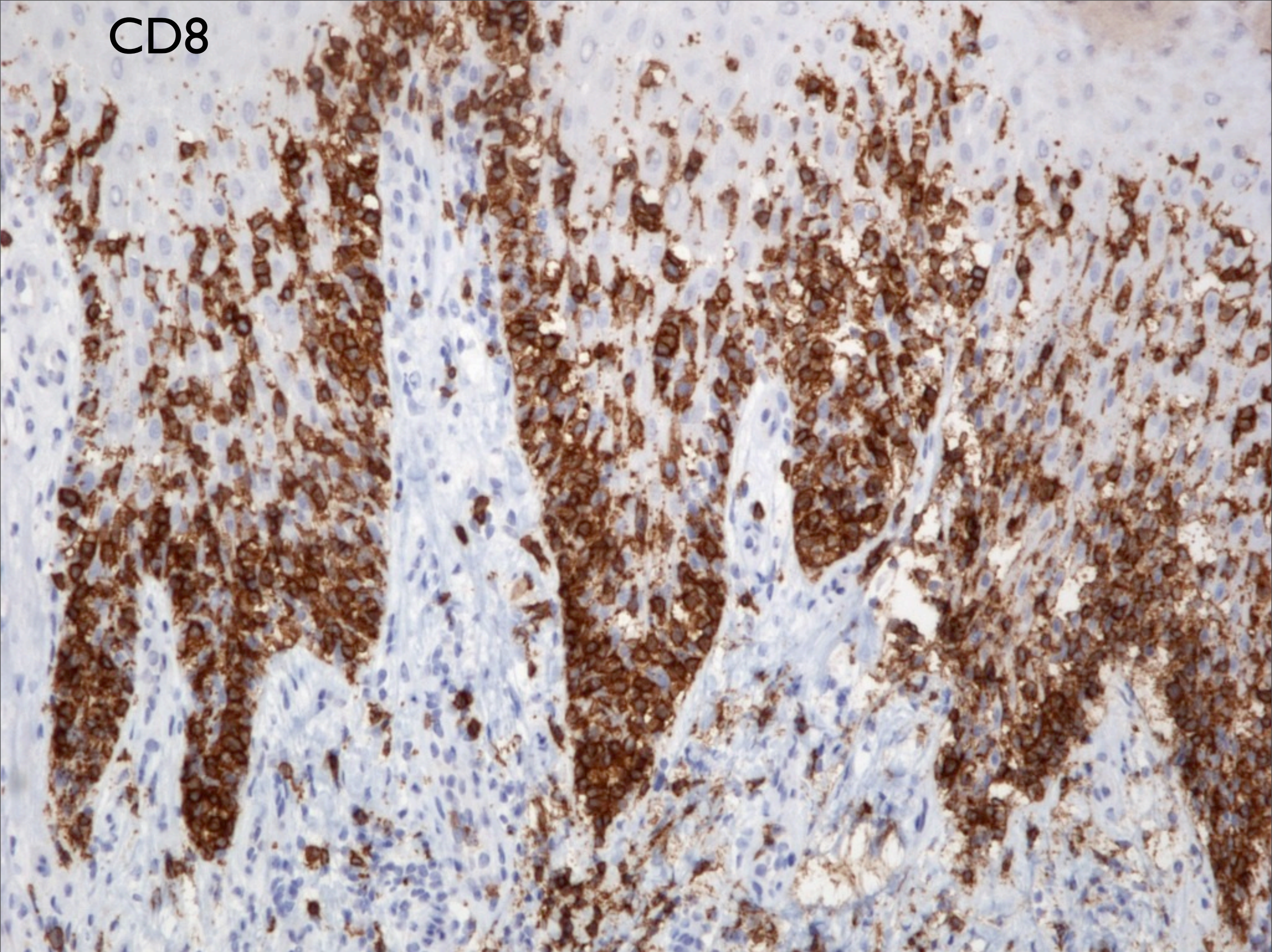
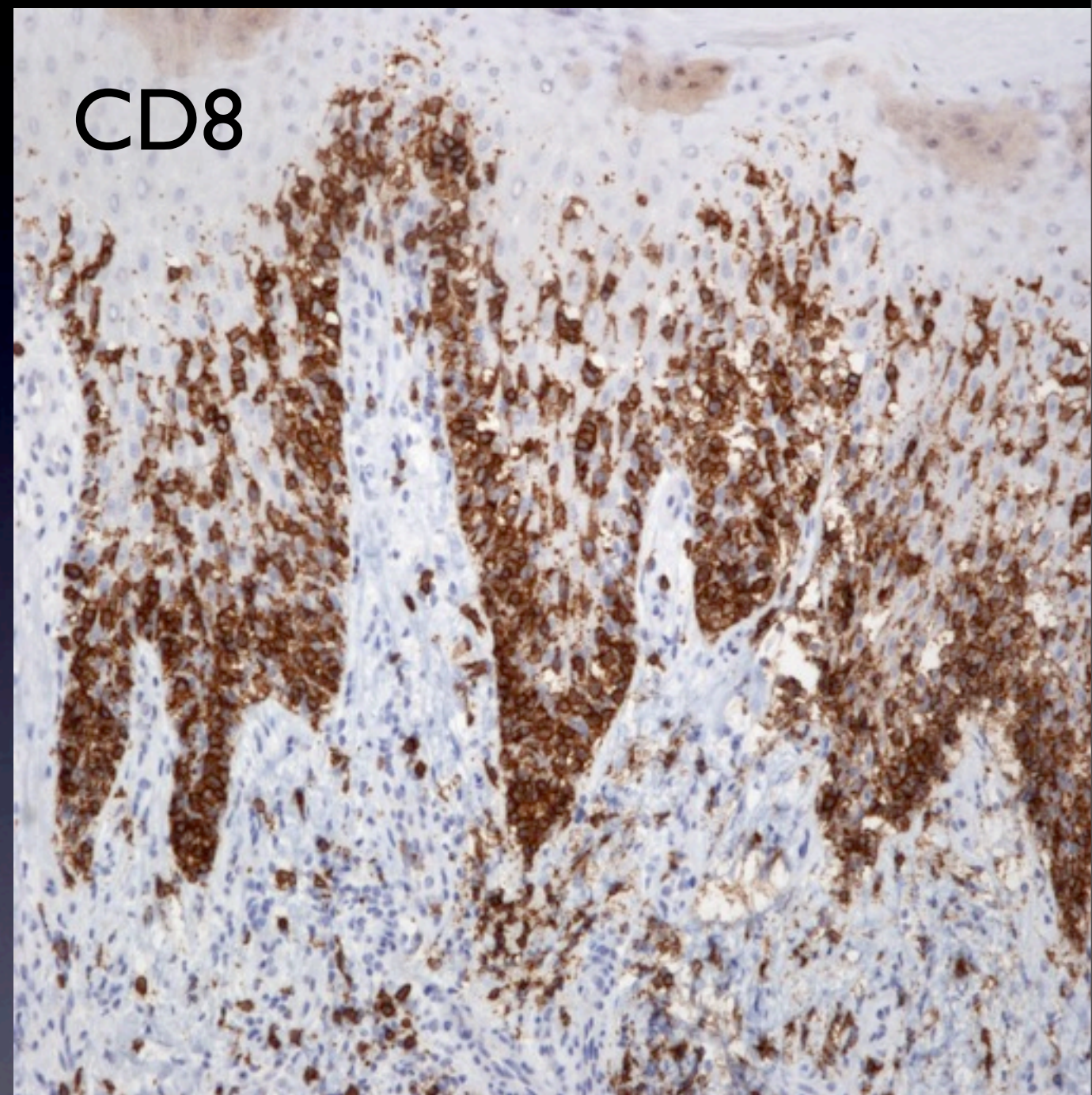
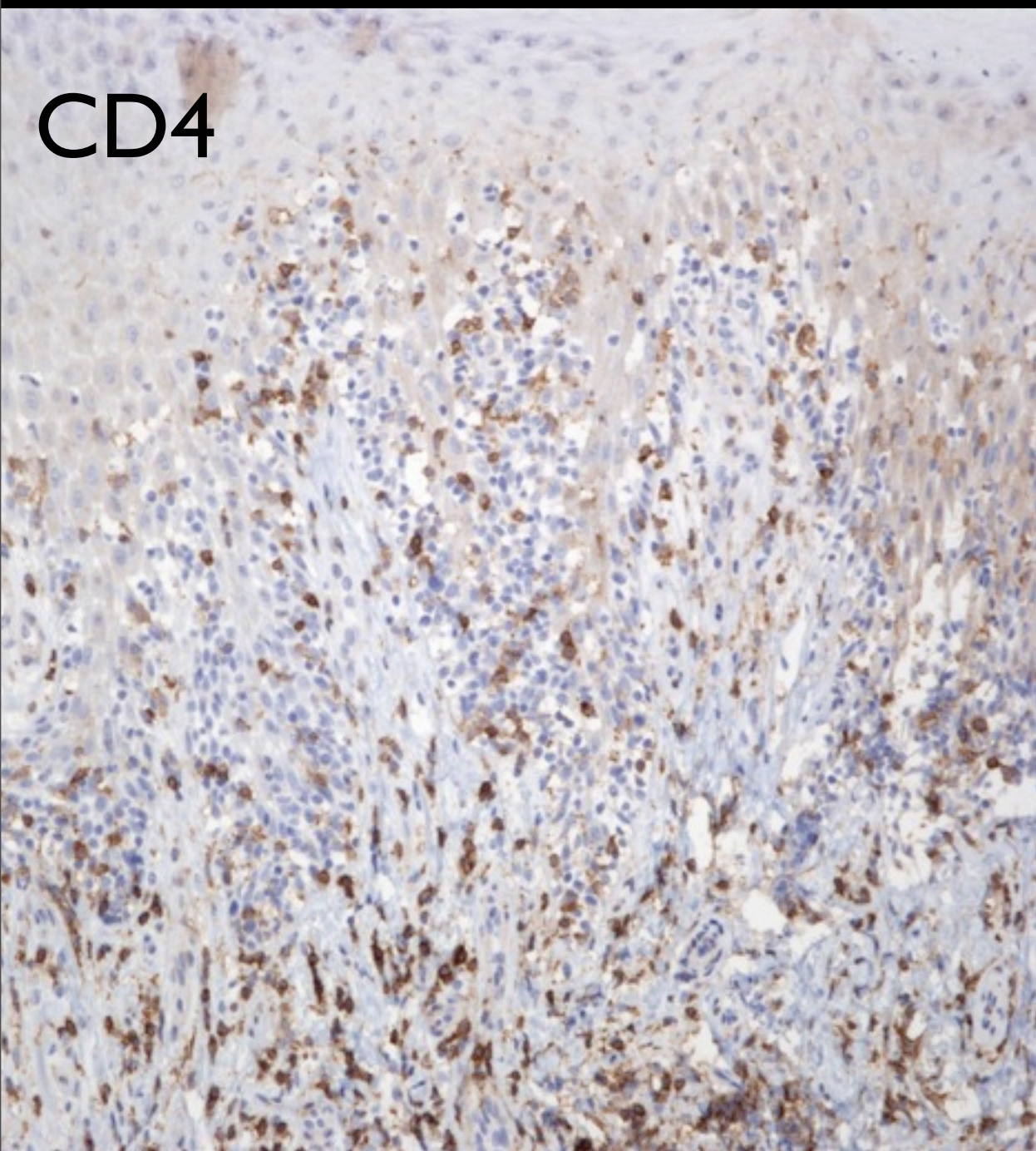
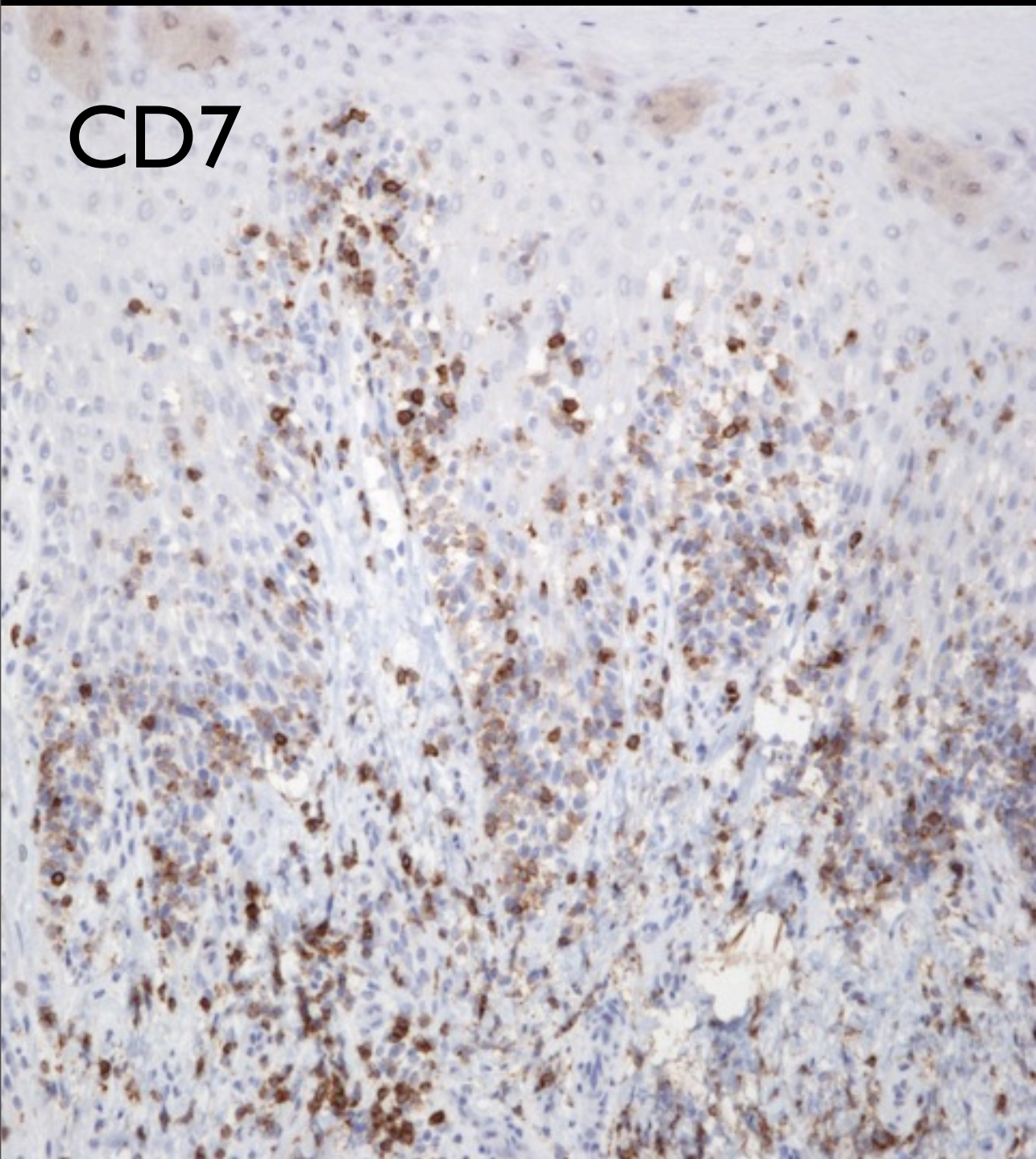


CD8

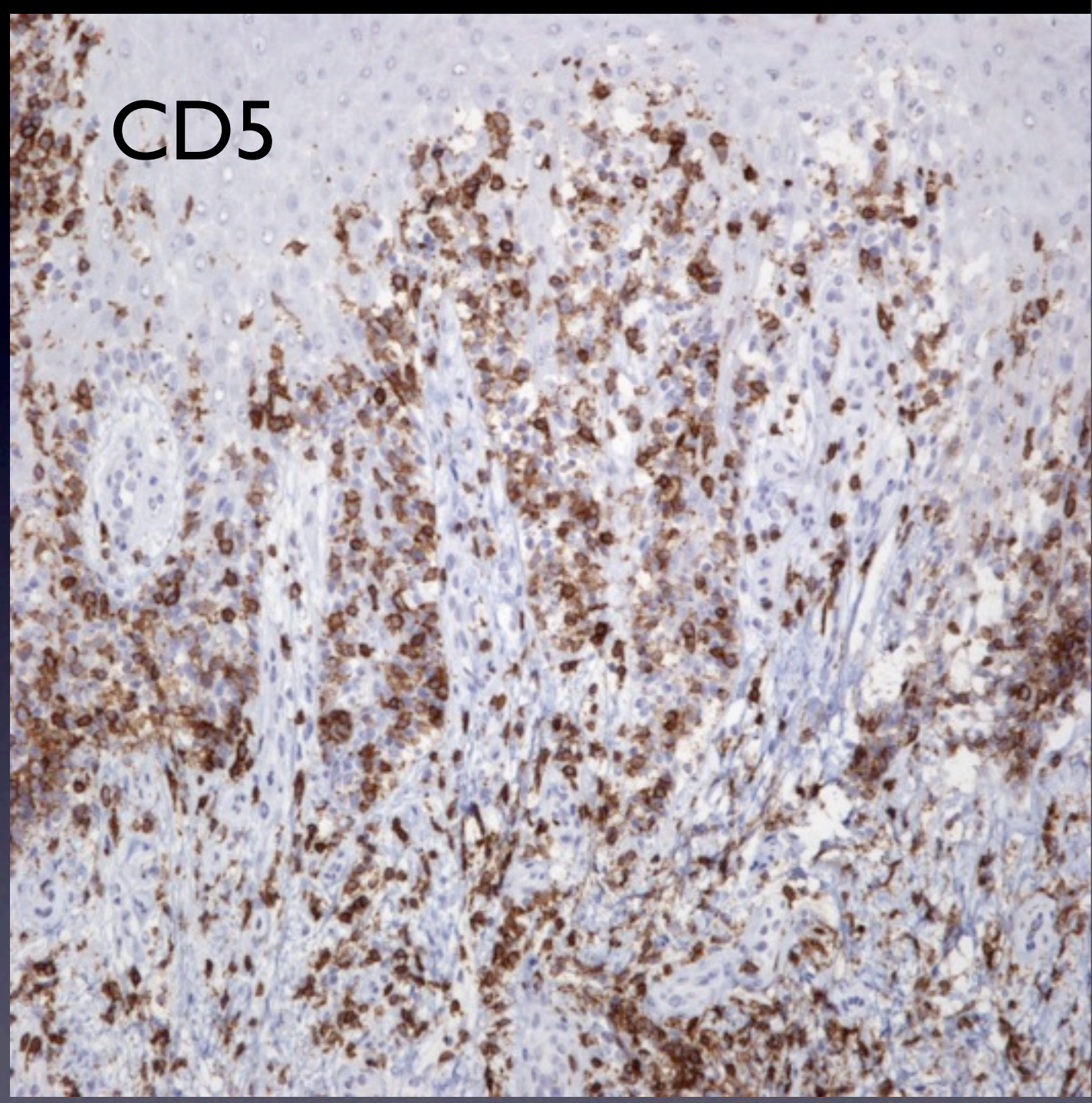




CD7



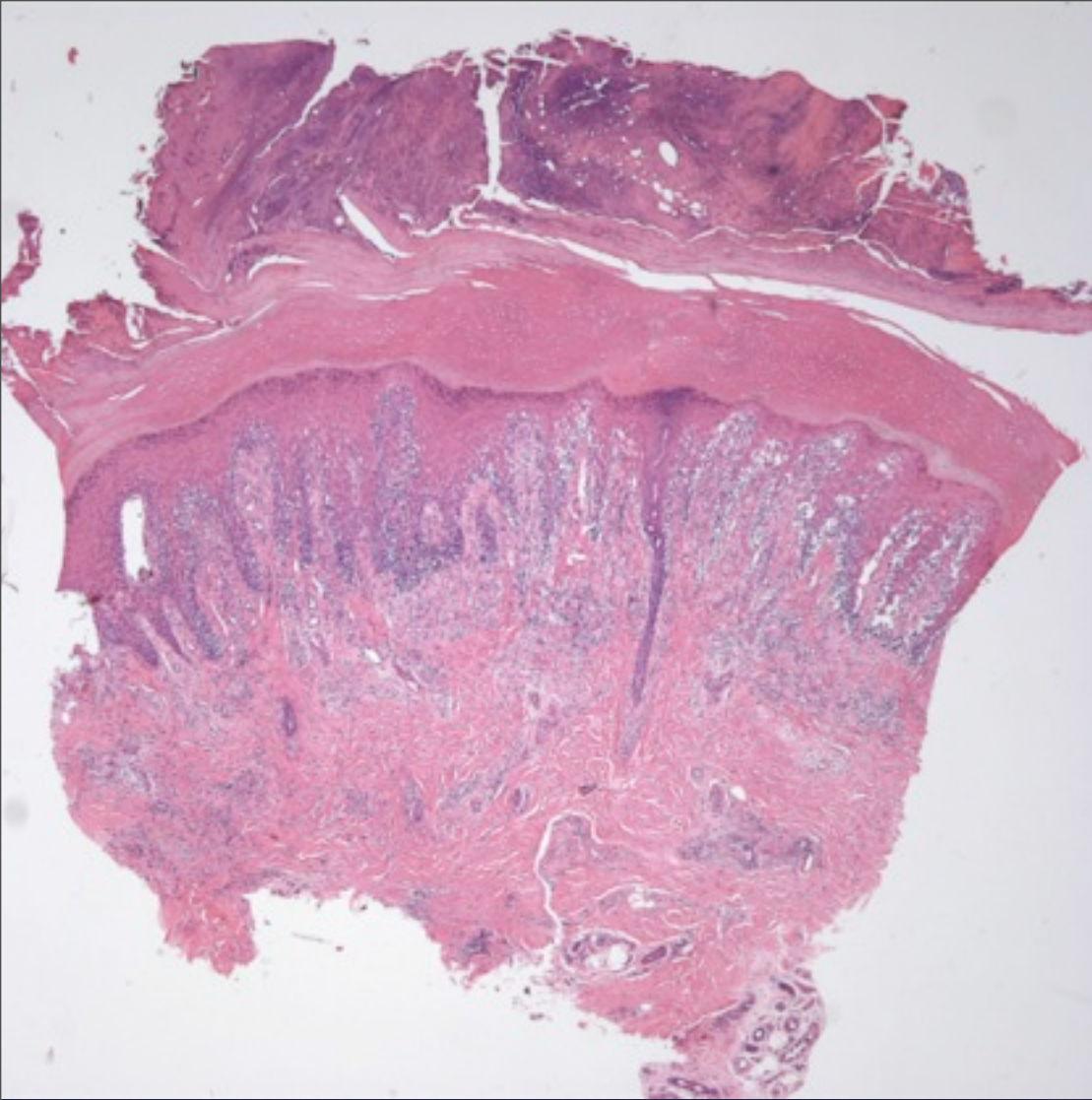
CD5



Woringer-Kolopp Disease (Pagetoid Reticulosis)

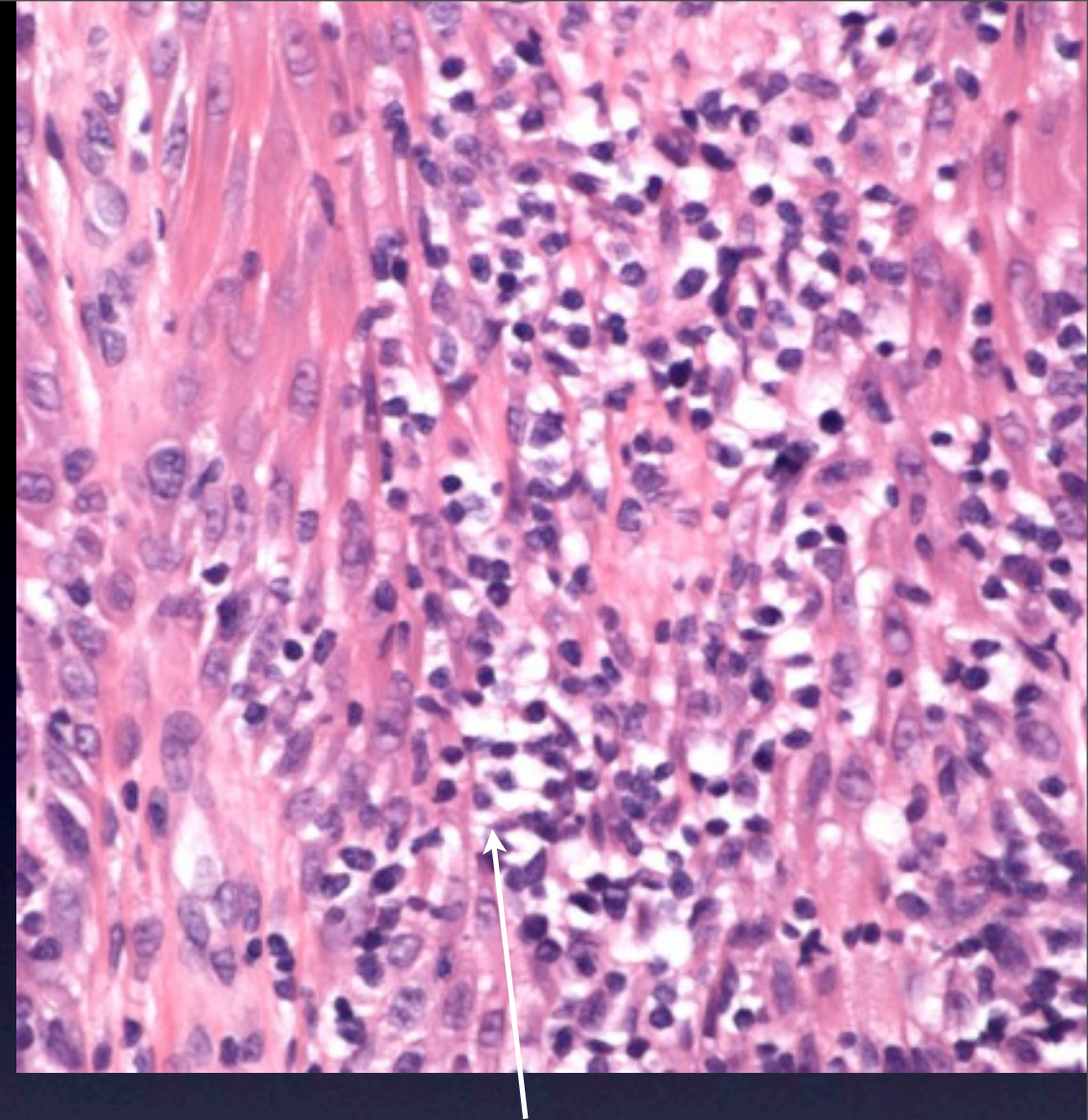
Notes

- This is a rare unilesional variant of mycosis fungoides, generally occurring in younger patients on the lower extremities
- Most common immunophenotype is CD4+, CD5-, CD7- but as in this case CD8+, CD7- cases have been reported.
- Rule out disseminated variant Ketrone-Goodman Disease



Acral location with
hyperkeratosis

Extensive epidermotropism
by lymphocytes



Hyperchromatic enlarged
and hyperconvoluted
lymphocytes